

# Avascular necrosis of the hip

Jonathan N Lamb,<sup>1</sup> Colin Holton,<sup>2</sup> Philip O'Connor,<sup>3</sup> Peter V Giannoudis<sup>2,4</sup>

<sup>1</sup>Leeds Institute of Rheumatic and Musculoskeletal Medicine, School of Medicine, University of Leeds

<sup>2</sup>Academic Department of Trauma & Orthopaedics, School of Medicine, University of Leeds, Leeds General Infirmary

<sup>3</sup>Department of Radiology, Leeds Teaching Hospitals NHS Trust

<sup>4</sup>NIHR Leeds Biomedical Research Centre, Chapel Allerton Hospital

Correspondence to: J N Lamb j.n.lamb@leeds.ac.uk

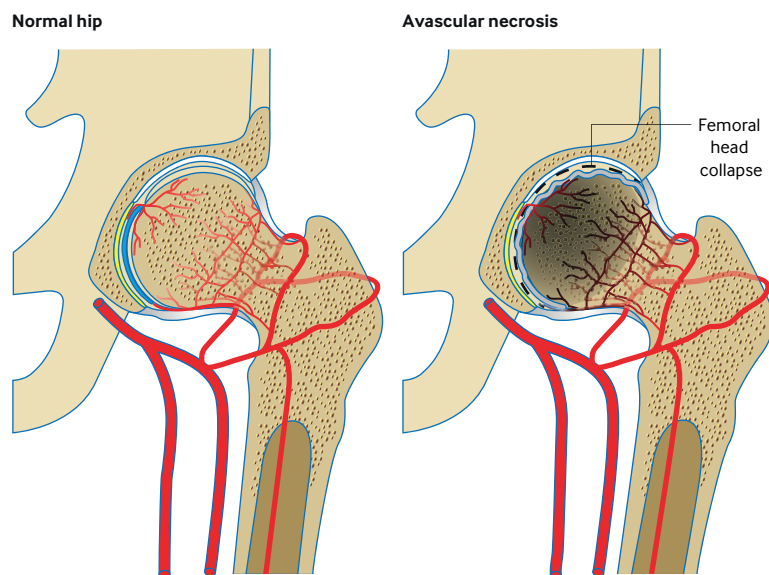


0.5 HOURS



See <http://learning.bmj.com> for linked learning module

**A 36 year old woman presents to her GP with a history of left groin pain radiating to the knee. The pain is severe, worse on walking, and associated with a limp. The patient revisits the GP a year later with persistent pain despite analgesia. Plain radiographs of the hip and knee show slight narrowing of the hip joint space with no other features, and she is referred to a secondary care orthopaedic clinic. A magnetic resonance imaging (MRI) scan of the hip shows classic features of avascular necrosis of the femoral head (AVNFB) with collapse.**



## What is avascular necrosis of the femoral head?

Avascular necrosis of the femoral head (AVNFB) causes loss of integrity of subchondral bone structure due to abnormal microcirculation. The underlying pathogenesis is unclear;<sup>1</sup> risk factors are likely to affect microcirculation in some way but this has not been confirmed by research. The common end point is abnormal microcirculation and necrosis. Subchondral bone subsequently collapses, which leads to progressive secondary arthritis.

Mean age of presentation in the UK is 58.3 years, with a prevalence of two per 100 000 patients.<sup>2</sup> On average, AVNFB occurs earlier in life than typical osteoarthritis. It is more common in men, and the highest prevalence is in men aged 25 to 44 and women aged 55 to 75.<sup>3</sup> In the UK it is the third most common indication for total hip replacement in people under 50.<sup>4</sup>

The following factors are associated with an increased risk of AVNFB:<sup>3,5</sup>

- High levels of blood triglycerides, total cholesterol, low density lipoprotein cholesterol, and non-high density lipoprotein cholesterol
- Male sex
- Urban residence
- Family history of AVNFB
- Heavy smoking
- Alcohol abuse
- Overweight
- Coagulopathies
- Vasculopathies
- HIV
- High exposure to steroids, chemotherapy, and immunosuppressant medication.

Steroids have been shown to increase odds of osteonecrosis (non-site specific) by a factor of three and immunosuppressants by a factor of six. Zhao reported that the odds of AVNFB were 35 times greater in patients taking corticosteroids and six times greater in patients with alcoholism.<sup>3</sup>

### WHAT YOU NEED TO KNOW

- Common risk factors for AVNFB are alcoholism, use of steroids, chemotherapy and immunosuppressant medication, and sickle cell anaemia
- Consider MRI scan of the hip and referral to an orthopaedic team if a patient has a painful hip for longer than six weeks with normal radiographs
- Early treatment improves the chances of hip survival by up to 88% at seven years

### EDUCATION INTO PRACTICE

- How often do patients with normal plain radiographs get reassessed and referred in your practice if there is ongoing hip pain?
- How will this article help you identify those patients most at risk of AVNFB?
- Have you or your colleagues seen a patient with AVNFB? How did they present?

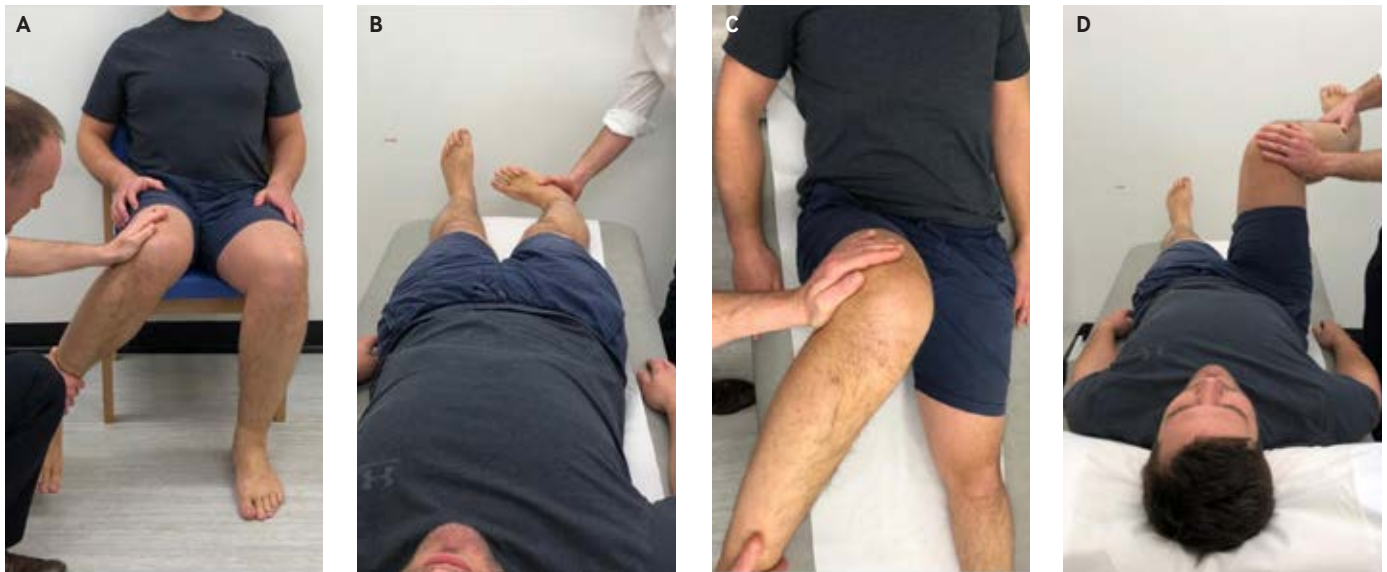

Fig 1 | Demonstration of hip rotation to elicit hip pain with the patient sitting (A) and supine (B, C, D)

#### A PATIENT'S PERSPECTIVE

Our patient was severely debilitated by the pain in her hip. She had recently given birth to her second child and was struggling to cope at home. She felt her concerns were not taken seriously because she was young. She hopes that this article will educate primary care teams about the potential problems associated with AVNFH and how they might be averted for future patients.

Our patient was reluctant to undergo total hip replacement and underwent novel treatment: core decompression with local stem cell therapy and distraction with an external fixator, which has improved symptoms and delayed the need for a total hip replacement.

#### Why is it missed?

AVNFH is rare. Patients with the condition can have coexisting chronic rheumatic and haematological problems. This may lead to diagnostic uncertainty, particularly given the use of chemotherapy, immunomodulatory agents, and steroids in these conditions, which are all risk factors for AVNFH.

A physical examination can help identify the anatomical structures that might be causing the pain, since hip pain can originate from multiple hip and non-hip areas. Presentations may be missed because accurate reproduction of groin pain on isolated hip movements can be challenging to elicit in a primary care setting due to time and space constraints.

Normal plain radiographs in the early stages of AVNFH can be falsely reassuring and delay appropriate referral. If the plain radiograph is negative and the patient continues to complain of hip pain, the doctor may give a diagnosis of non-specific hip pain (given that musculoskeletal presentations are common in primary care) and send the patient for physiotherapy.

Of new presentations, 18.75% are diagnosable only with MRI and are easily missed on normal plain radiographs.<sup>3</sup> Only the MRI scan is diagnostic.

#### Why does it matter?

Early diagnosis and referral are essential since bone destruction normally occurs within two years of disease onset, making joint preserving intervention impossible.<sup>6</sup> Early identification of AVNFH gives the multidisciplinary team time to change medical treatments which might be provoking onset of AVNFH. Surgical decompression of the femoral head reduces the need for further surgery in the short to medium term but is only suitable for the earliest stages of disease.<sup>5</sup> Once patients have progressed to secondary hip arthritis, joint replacement is usually inevitable. However, given the younger age of patients with AVNFH, the lifetime risk of revision surgery and associated morbidity is great.

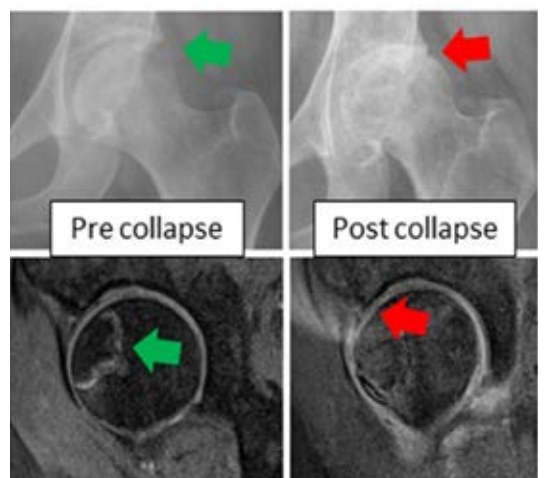


Fig 2 | Typical changes seen on plain radiograph (top) and MRI (bottom) of the hip in early and late AVNFH. The appearance of early AVNFH is not apparent on plain radiograph but is visible on MRI

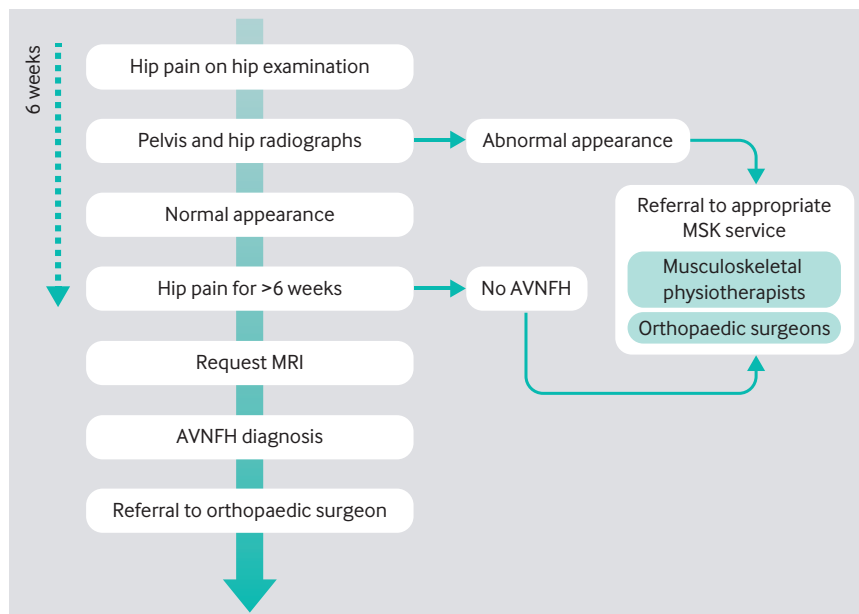


Fig 3 | Proposed pathway for managing AVNFH in a primary care setting

#### Red flags requiring referral or further assessment

- Hip pain for more than six weeks with normal hip radiograph
- Patients presenting with hip pain and risk factors including
  - previous unilateral AVNFH
  - alcohol excess
  - high exposure to steroid therapy
  - immunologic therapy
  - chemotherapy
  - sickle cell disease and other coagulopathies
  - HIV
  - recent pregnancy

## How is AVNFH diagnosed?

AVNFH diagnosis starts with a careful history and examination to determine that the hip is the source of pain. Ultimately an MRI is required to diagnose AVNFH and may also diagnose other causes of hip pain.

### A careful history

A history showing pain lasting longer than six weeks, typically located in the groin and thigh and which is worse on weight bearing and movement is key.<sup>6</sup> Usually there is no history of trauma. Ask about risk factors and refer for MRI of the hip if the patient has any “red flags” (box). AVNFH is often bilateral and the risk of bilateral AVNFH is highest within two years of unilateral diagnosis.<sup>6</sup>

### Examination

Reproduction of pain in the groin, thigh, and anterior aspect of knee with isolated thigh rotation will not diagnose AVNFH, but will help to differentiate hip pain from pain originating from the spine and knee. This can be performed with the patient sitting or supine (fig 1).

### Radiological tests

Early AVNFH is not apparent on plain radiographs. If the patient continues to be in pain, further

investigation and referral is warranted. AVNFH is diagnosed on MRI of the hips,<sup>7</sup> which may also diagnose a breadth of treatable hip pain (such as rheumatological disease, musculoskeletal disease, and bony disease) when carefully correlated with clinical symptoms<sup>8</sup> (fig 2).

Other investigations, such as blood tests, should only be considered if indicated for other reasons or if there is a high suspicion of rheumatological disease or infection.

### Referral

If the patient has signs of AVNFH on MRI of the hip, refer to an orthopaedic surgeon for consultation (fig 3).

In secondary care, AVNFH diagnosis should be shared with any care teams involved in the administration of steroids, chemotherapy, and immunologic therapy.

Medical and surgical treatment depend on the patient characteristics and stage of AVNFH. Medical treatment of pre-collapse disease with prostacyclin analogues and bisphosphonates may reduce symptoms and prevent loss of joint congruity but their efficacy is not currently well defined.<sup>6</sup> Surgically,

treatment remains controversial, but most patients with pre-collapse AVNFH are offered core decompression surgery with or without adjunctive pharmacological therapy to reduce pain and potentially prevent the need for total hip replacement in 88% of patients for up to seven years.<sup>9 10</sup>

Postoperative recovery involves a period of non-weight bearing for 12 months and gradual return to work and driving at 8 weeks. Full benefit is usually felt at 12 months after surgery. Specialist tertiary centres may offer novel treatments such as bone grafting and osteotomies to encourage vascular regrowth and unload damaged hip articular surface, respectively. Once collapse has occurred, total hip replacement can give patients rapid, reliable pain relief and improved function but is associated with the risk of future revision, particularly in younger patients. A full description of all the options is beyond the scope of this article and patients should discuss all available options with their surgeon to enable informed shared decision making.

Competing interests: None declared.

Cite this as: *BMJ* 2019;365:l2178

Find the full version with references at <http://dx.doi.org/10.1136/bmj.l2178>

## HOW PATIENTS WERE INVOLVED IN THIS ARTICLE

The case was an abbreviated version of a patient's experience with AVNFH recorded following patient interview. The paper was shared with a patient who emphasised her frustration when initially dismissed from primary care with symptoms of hip pain.

# Giant cell arteritis

Karina Lazarewicz,<sup>1</sup> Pippa Watson<sup>2</sup>

<sup>1</sup>Rheumatology, Manchester University Foundation Trust, Trafford Hospital

<sup>2</sup>Rheumatology, Manchester University Foundation Trust, Wythenshawe Hospital

Correspondence to: K Lazarewicz karinalazarewicz@yahoo.co.uk

Giant cell arteritis (GCA) is an inflammatory disease that affects medium and large blood vessels, classically the extracranial branches of the external carotid arteries. Inflammation in the wall of the affected artery may cause headache, scalp tenderness, jaw and tongue pain, and visual disturbances, but can also present with systemic or other less common symptoms, so that diagnosis can be challenging. It is a rare disease affecting 2.2 per 10 000 patient-years in the UK.<sup>1</sup>

Consequences can be serious if the diagnosis is delayed, and may include visual loss, stroke, and aortic aneurysm. Many patients with GCA first present to their general practitioner or local emergency department. The most common presenting symptom of GCA is headache (76%)<sup>1</sup> but given its relative rarity, other causes of headache are much more common in these settings. Glucocorticosteroids are the mainstay of treatment, but at high doses and for prolonged periods of time are associated with substantial side effects. In April 2019, the National Institute for Health and Care Excellence (NICE) licensed tocilizumab for patients with refractory or relapsing disease.<sup>2</sup> This article provides a practical update for non-specialists with particular emphasis on making a diagnosis and initial management. It also discusses the new NICE guideline on tocilizumab and its likely impact.

## WHAT YOU NEED TO KNOW

- Giant cell arteritis (GCA) is a medical emergency that requires immediate treatment with glucocorticosteroids
- Headache is the most common presenting symptom but is not always present
- Refer patients with suspected GCA and visual symptoms such as blurring, diplopia, or visual loss immediately to ophthalmology specialists, as untreated GCA with eye involvement can lead to loss of eyesight
- Refer patients without visual symptoms urgently to rheumatology specialists
- The mainstay of treatment is high dose prednisolone; in some patients with refractory or relapsing disease, tocilizumab can be added to prednisolone to treat GCA and act as a steroid sparing agent



0.5 HOURS



See <http://learning.bmj.com> for linked learning module

## Presentation

**Who gets it?** GCA is relatively rare in a non-specialist setting, with an incidence of 7-29/100 000 population aged >50 in Europe.<sup>3</sup> It is more prevalent in people of northern European ancestry.<sup>3</sup> Frequency increases with age, being very rare in those under 50, with a mean age of onset of 70.<sup>4</sup> As with many other autoimmune diseases, it is more common in women than men (2-6 times more likely).<sup>4</sup>

**What causes it?** Inflammation in the affected blood vessel wall, for example in the carotid artery and its branches, is characterised by the presence of macrophages (which may fuse to form the characteristic giant cells) and CD4+ T lymphocytes.<sup>5</sup> This leads to thickening of the intima, and results in reduced blood flow and ischaemia, which is the main cause of pain in the areas that are supplied by the affected vessel (eg, temporal artery involvement can lead to headache). The release of cytokines leads to systemic symptoms.

**Why does it matter?** Early diagnosis and treatment of GCA can prevent development of serious complications, such as visual loss. Even when treated, visual loss can occur and be permanent. Before corticosteroid treatment was used to treat GCA, visual loss was noted in 30-60% of patients.<sup>6</sup> If left untreated, up to half of individuals with GCA could sustain unilateral visual loss within days to weeks of symptoms.<sup>7</sup>

**How do patients present?** Symptoms and signs (table 1) frequently occur because of the involvement of arteries arising from the cranial branches of the aortic arch, particularly the extracranial branches of the carotid arteries (fig 1).

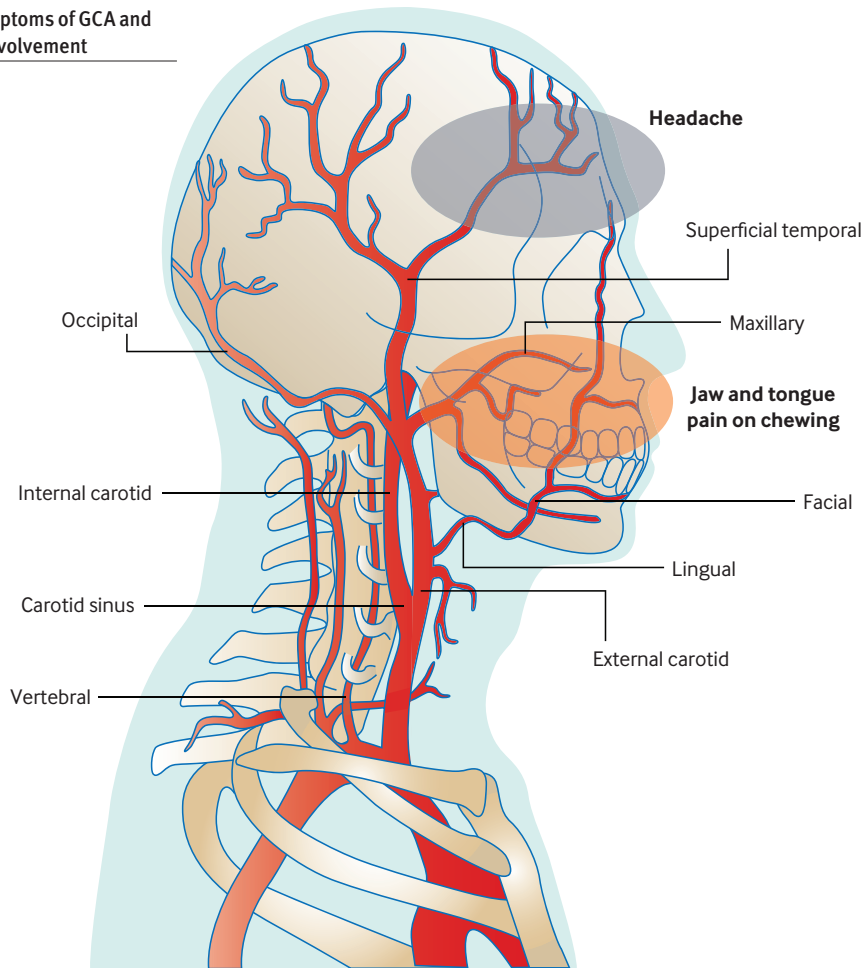
Table 1 | Clinical features associated with giant cell arteritis<sup>1,4</sup>

Symptoms/clinical features	Present at diagnosis (%)
Temporal headache	52
Jaw claudication	34
Scalp tenderness	31
Visual symptoms	20-37
Aortic aneurysm	20
Polymyalgia rheumatica	40-60
Constitutional symptoms	30-60

## HOW PATIENTS WERE INVOLVED IN THE CREATION OF THIS ARTICLE

We have discussed living with GCA with several of our patients. Our patients highlighted many important issues, including difficulty obtaining a diagnosis, and were extremely keen that we familiarise more doctors with the condition. They were unanimous about the need to improve diagnosis (such as by using ultrasound) and the side effect burden that is associated with long term glucocorticoid use. We have used this to inform the writing of our article.

Fig 1 | Symptoms of GCA and arterial involvement



#### EDUCATION INTO PRACTICE

- Would you consider GCA as a diagnosis in a patient who didn't present with a headache?
- Would you start glucocorticoid treatment before referral?
- Think about the last time you reviewed someone with GCA. Did you discuss potential steroid side effects and ways of minimising their impact? How might you do this more next time?

#### The American College of Rheumatology classification criteria<sup>15</sup>

At least three of five criteria must be present—sensitivity 93.5%, specificity 91.2%

- Age at onset >50
- New onset headache
- High erythrocyte sedimentation rate (>50 mm/hour by the Westergren method)
- Abnormal temporal artery on palpation
- Changes consistent with GCA on biopsy

## Assessing a patient: history and examination

### Ask about

**Headache**—this is the most common symptom, but it isn't always present. When present it is usually a severe temporal headache although GCA can present with occipital or parietal pain.<sup>8</sup> It is quite often insidious in onset but can also be acute. The pain is described as dull in nature but this varies.

**Visual symptoms**—ask about visual symptoms in anyone presenting with a headache. Is there partial or complete loss of vision or diplopia? Ask specifically about both eyes. If a patient has unilateral eye involvement, the likelihood of the other eye being affected at the same time is 20-50%.<sup>9</sup>

**Scalp tenderness**—is there scalp tenderness when brushing hair?

**Constitutional symptoms**—fatigue, weight loss, anorexia, and sweats or fevers are frequently present. However, differential diagnoses, such as infection and malignancy, should also be considered.

**Pain in the jaw on chewing (jaw claudication)**—this is the most common

ischaemic complication. Usually pain happens after minutes of chewing over the masseter muscle, due to its ischaemia.<sup>10</sup> Tongue claudication is very rarely the presenting symptom and is present in about 2-4% of patients.<sup>11</sup> Jaw (or tongue) claudication is associated with a high risk of ischaemic complications.<sup>12</sup>

**Proximal muscle pain and stiffness**—patients with coexisting polymyalgia rheumatica (PMR) may report muscle pain, particularly in the proximal arms and legs, and early morning stiffness usually lasting several hours. They often find it difficult to get out of bed in the morning.

### Examine

**Temporal arteries**—palpate the temporal artery to look for tenderness, beading that feels like small hard lumps, and/or decreased or absent pulsation, for example by comparing it with the other side.

**Vascular examination**—look for large vessel vasculitis features such as bruits (eg, carotid or subclavian artery), decreased

arterial pulsation, or a blood pressure differential between arms.

**Eyes**—check visual acuity and visual fields, looking for anterior ischaemic optic neuropathy secondary to GCA, which may present as monocular loss of vision (over hours to days). Some patients report altitudinal vision loss (either lower or upper half of the visual field is selectively affected) or scotoma. Check pupillary reflexes for a relative afferent defect secondary to optic nerve ischaemia, and perform fundoscopy. Fundoscopy findings are not specific to GCA and may include cotton wool patches, oedema, pale discs, or even haemorrhage.

**Scalp**—feel for tenderness over the scalp; do not limit your examination only to the skin overlying the temporal artery as arteries supplying the scalp can also be involved.

Perform a thorough general examination, including (but not limited to) cardiovascular, respiratory, and abdominal systems to exclude other differential diagnoses (table 2).

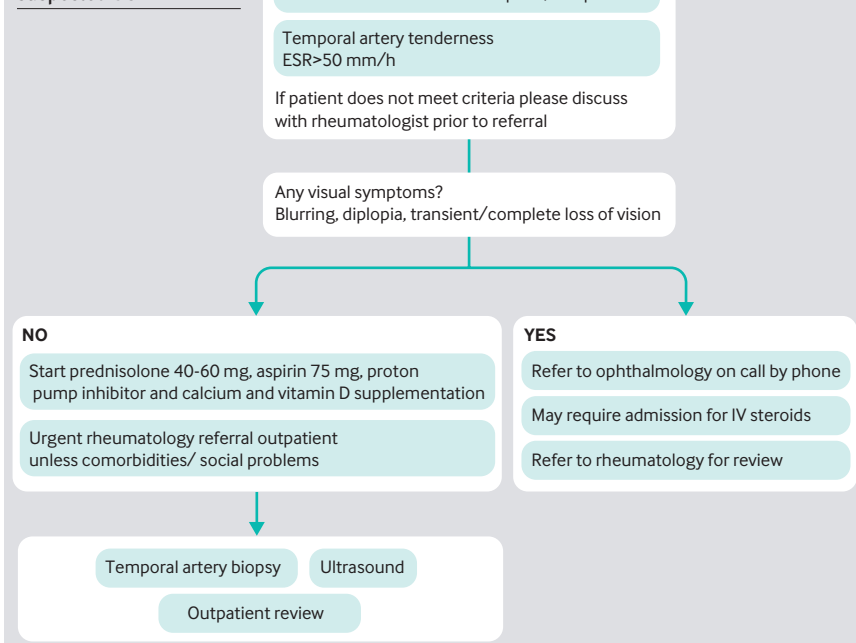
**Table 2 | Differential diagnoses<sup>4-14</sup>**

Differential diagnoses	Features to consider
<b>Headache</b>	
Headache of other origin (cluster, migraine, tension, etc)	Recurrent attacks, visual aura, eye watering, nausea, photosensitivity
Sinusitis	Runny nose, nasal discharge, fever, pressure behind the eyes and cheeks
Trigeminal neuralgia	Severe shooting pain over the side of the face that may feel like an electric shock, burning pain
Ophthalmic varicella zoster infection (shingles)	Pain and burning over the distribution of temporal artery, sensitivity to touch, fever, itching, rash, blisters
Skull metastasis	Cranial nerve signs, eg, diplopia, localised pain and tenderness
<b>High ESR/systemic features</b>	
Polymyalgia rheumatica	Proximal muscle pain and stiffness especially in the morning (bilateral shoulder or pelvic girdle), increased inflammatory markers, extreme tiredness, loss of appetite, weight loss. Good response to steroids
Small/medium vessel vasculitis, eg, polyarteritis nodosa, granulomatosis with polyangiitis	Involvement of other systems, eg, ENT respiratory, renal involvement
Endocarditis	New or changing heart murmur, splenic tenderness, Janeway lesions, Osler's nodes, haematuria
Malignancy, eg, lung cancer	Smoking history, haemoptysis, shortness of breath, cough
Temporomandibular disorder	Localised pain on chewing, speaking, or yawning; immediate onset; dull aching pain

**Table 3 | Investigations to consider**

Investigation	Why
Full blood count, urea and electrolytes, liver function test, C-reactive protein (CRP), erythrocyte sedimentation rate (ESR)	ESR and CRP are usually elevated in patients with GCA. Only 4% have a normal ESR; 83% are above 50 mm/h <sup>1</sup> Other typical findings include elevated alkaline phosphatase and thrombocytosis
Urine dipstick	Proteinuria or haematuria could indicate a small vessel vasculitis; haematuria could indicate endocarditis
Chest radiograph	Look for an aortic aneurysm Consider differential diagnoses such as lung cancer or small vessel vasculitis (looking for cavities)
CT head	Consider if predominant headache and atypical history
Temporal artery biopsy	Look for arteritis or atherosclerosis
Duplex ultrasonography	Look for hypoechoic "halo," occlusions, and stenosis

**Fig 2 | Example of local referral pathway for suspected GCA**



## Investigations

Recommended investigations are presented in table 3.

### Classification

When classifying patients with vasculitis, the American College of Rheumatology criteria (box) may be helpful, but these are not diagnostic criteria, and should not be used as such. However, the criteria are straightforward to use and may help to start early treatment and trigger specialist referral.

### Referral

Refer all patients with suspected GCA urgently to secondary care. If there is visual involvement refer immediately for ophthalmology review. Refer other cases urgently for rheumatology outpatient review to be seen as soon as possible, usually within two weeks. Commence glucocorticosteroids in primary care as soon as the diagnosis is suspected. Many specialist centres have a fast track GCA pathway (fig 2), which is likely to include prompt review, temporal artery biopsy, with or without ultrasound. Be aware of your local arrangements and discuss atypical cases early with your local specialist.

Temporal artery biopsy is currently the gold standard for diagnosis in all patients with suspected GCA. According to the 2010 British Society of Rheumatology guidelines for the management of GCA, a unilateral biopsy of at least 1 cm should be done in an experienced surgical unit. The procedure is usually carried out under local anaesthesia. A positive result means that inflammatory changes are confirmed. According to American College of Rheumatology 1990 criteria for classification of GCA, the specificity of temporal artery biopsy is 73.1% and sensitivity is 92.9%. Do not delay steroid treatment waiting for the results as the diagnosis of GCA is mainly based on clinical judgment, and even with a negative biopsy a patient can still have GCA. Biopsy remains positive for 2-6 weeks after commencing steroids, although the sooner the biopsy is performed the greater the chance of it being positive.<sup>16</sup> One of the biggest challenges is the high false negative rate due in part to the presence of skip lesions.

Ultrasound is increasingly being introduced as part of the assessment of patients with suspected GCA, to visualise temporal and axillary arteries. Typical findings include a halo suggestive of vessel wall oedema. Monti et al<sup>17</sup> found that ultrasound had a sensitivity of 63% and specificity of 100% in routine clinical practice. Introduction of this technique in their centre led to a decrease in their biopsy rate from 42% to 24%. Other techniques, such as F-18 FDG-PET/CT, are particularly useful in cases where there are systemic but no localising features.